La Protesi di Spalla

Marco Ferraresi

Casa di Cura
S. Clemente
Mantova

Il complesso articolare della spalla dal punto di vista anatomico e biomeccanico va considerata composta da 5 “articolazioni”

gleno-omerale

acromion-claveare

sterno-clavicolare

acromion-omerale

scapolo-toracica

si possono considerare piani di scorrimento ma sono di fondamentale importanza dal punto di vista biomeccanico e nella genesi della patologia

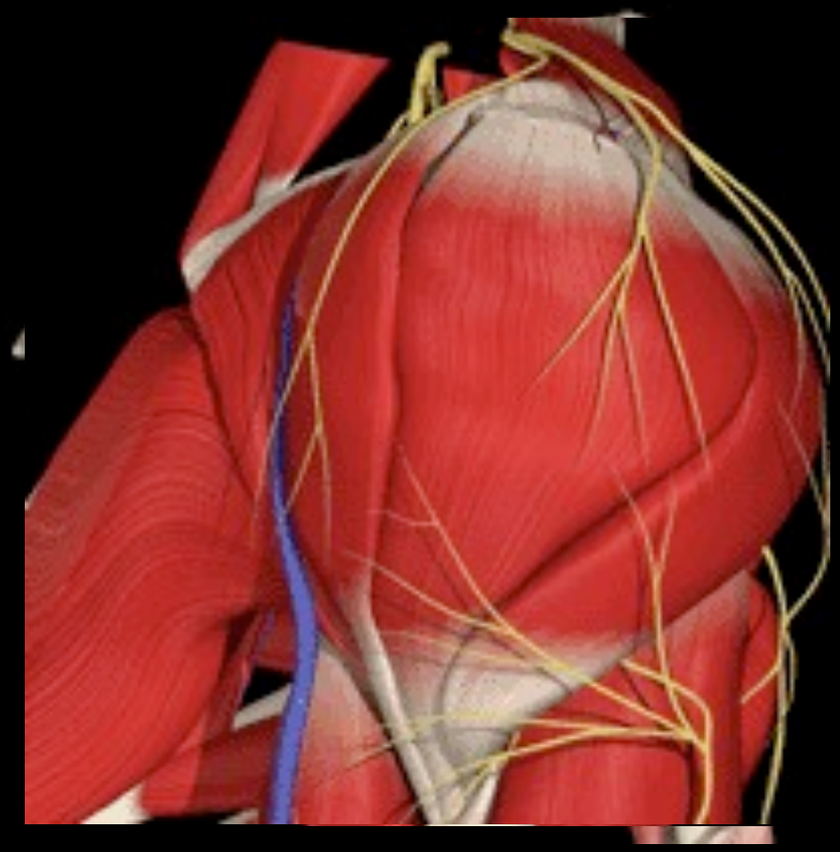

La Spalla non è quindi un'unica articolazione ma il suo movimento è legato a una sincronia perfetta delle diverse articolazioni stabilizzate da complessi capsulo legamentosi, e attivate da gruppi muscolari differenti.

La stabilità e la mobilità in questa articolazione devono necessariamente trovare un compromesso.

Molte delle patologie della spalla sono in effetti localizzate nelle strutture deputate alla stabilità (capsula - complesso capsulo-labrale) e alla motilità (tendini della cuffia)

Fattori Statici

Congruenza articolare

Versione articolare

Cercine glenoideo

Capsula ed i legamenti.

Fattori Dinamici

Cuffia dei rotatori

CLB

pressione negativa

Movimento Scapolo-toracico

L'Organizzazione Mondiale della Sanità indica le malattie reumatiche – artrosi, osteoporosi, lombalgie e reumatismi infiammatori – come la prima causa di dolore e disabilità in Europa.

Da sole, rappresentano la metà delle malattie croniche che colpiscono la popolazione al di sopra di 65 anni.

Dati epidemiologici italiani pubblicati nel 2005 dimostrano che il 26,7% della popolazione di età superiore a 18 anni sarebbe affetto da una malattia reumatica e, in particolare, l'8,9% da artrosi.

L’ Artrosi è un processo degenerativo che ha origine nella cartilagine articolare ma che, gradualmente, coinvolge le altre strutture articolari come l’ osso subcondrale (geodi, osteofiti), la membrana sinoviale, la capsula articolare.

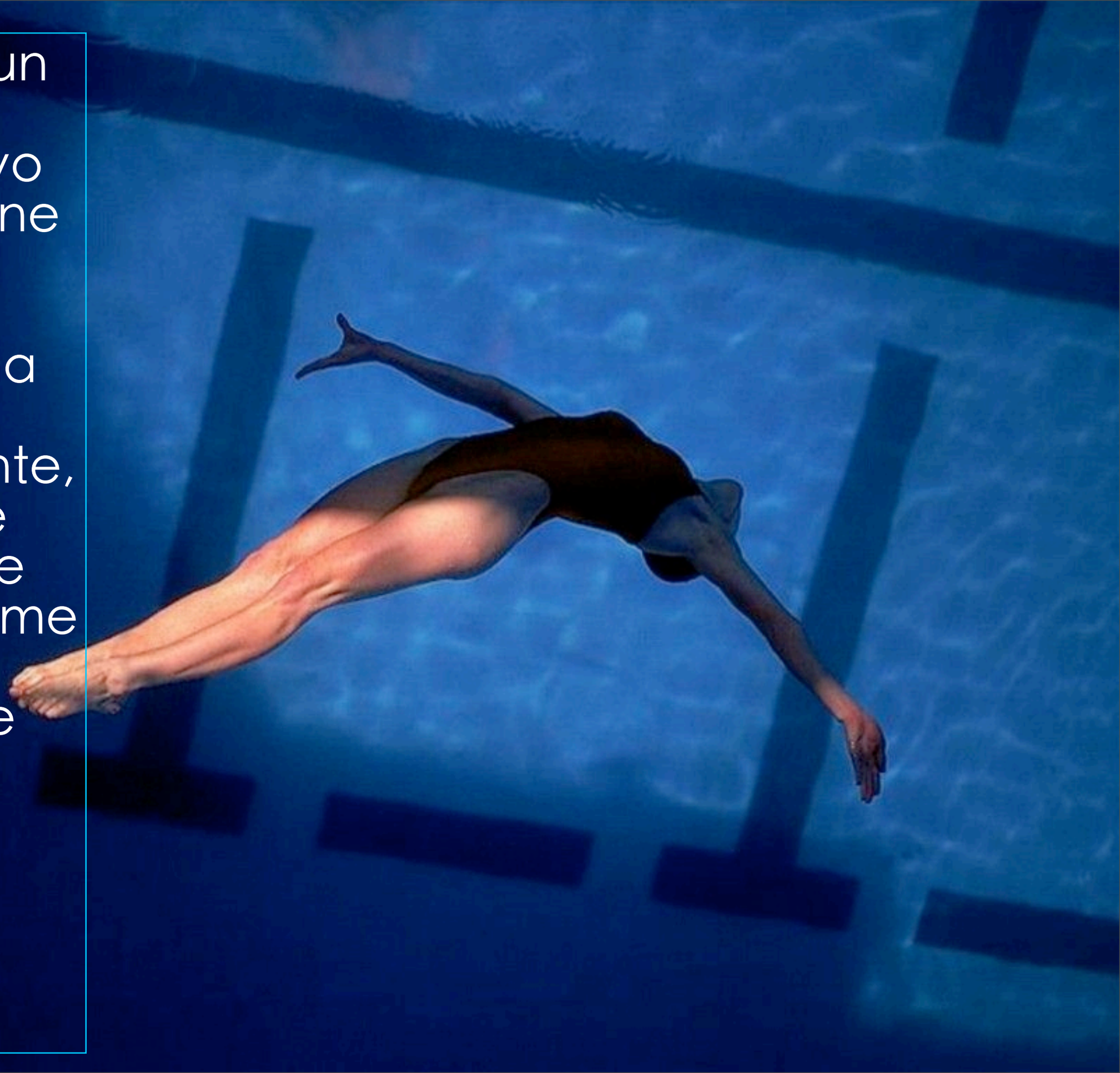

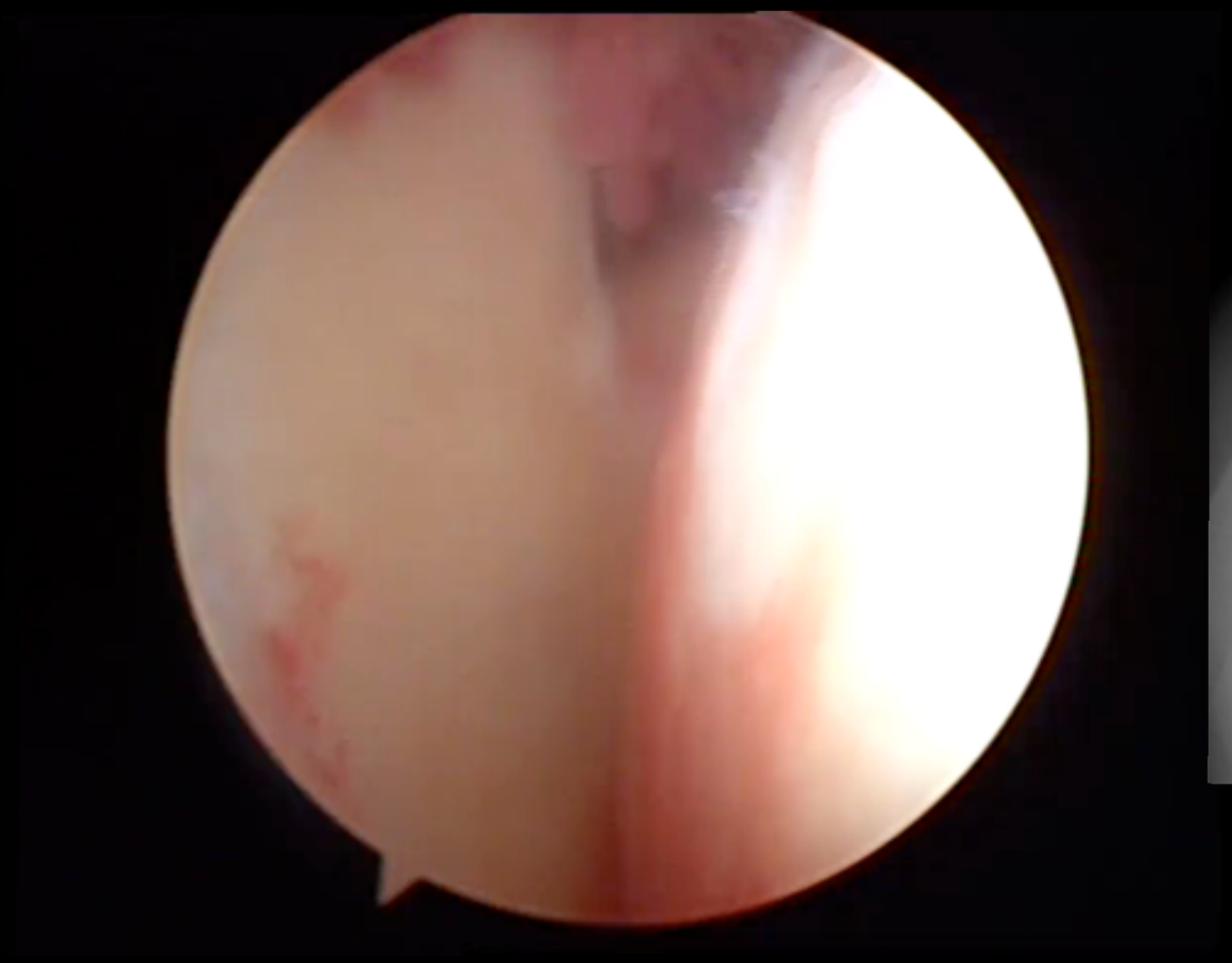

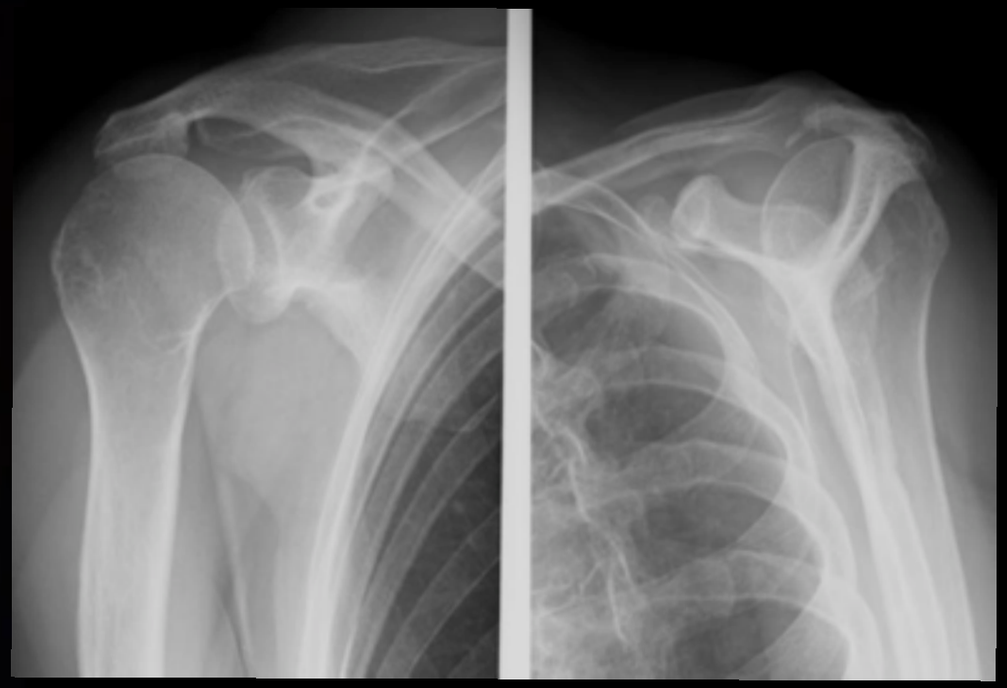

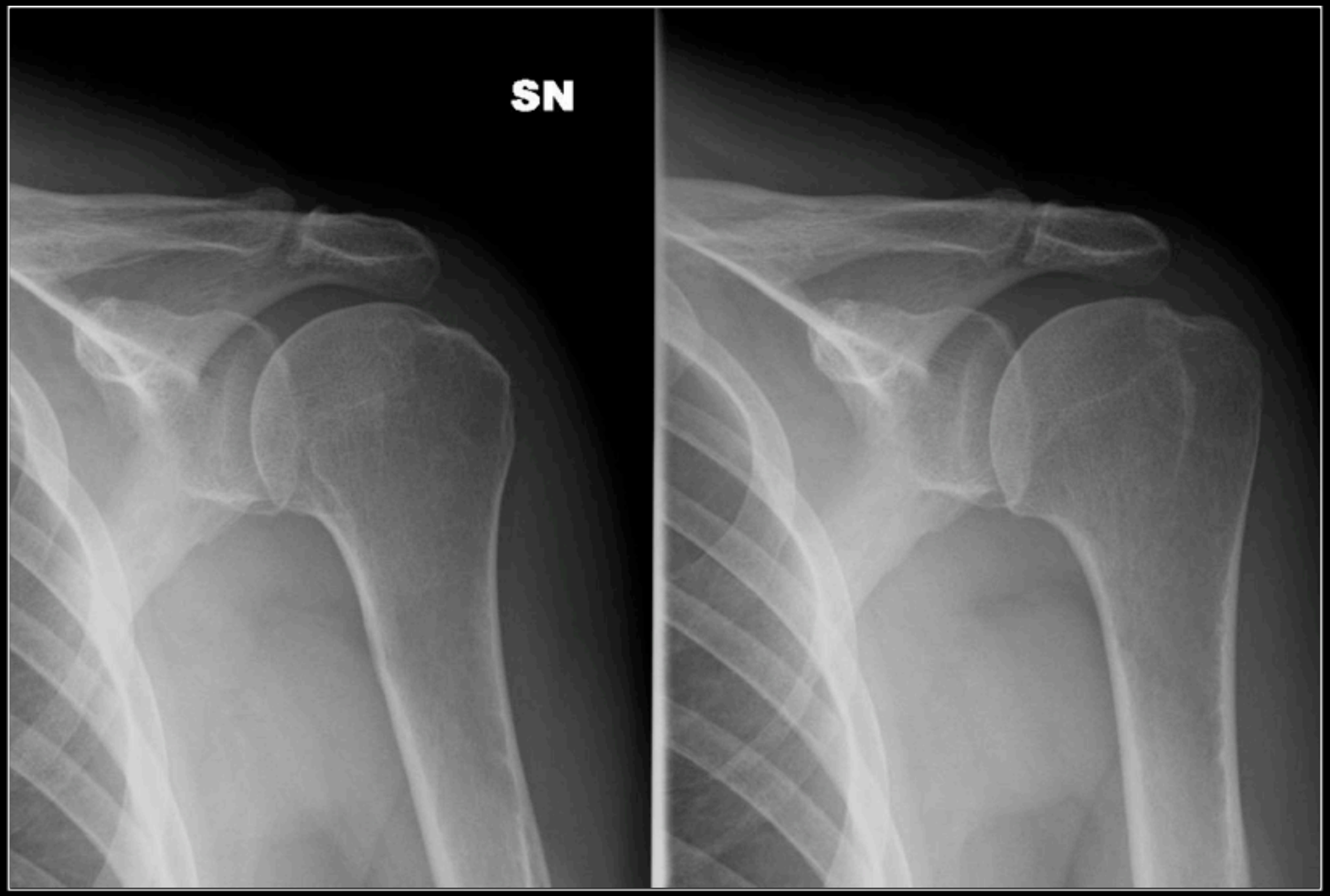
SN

Artrosi Concentrica

Artrosi eccentrica
Cuff Arthropaty

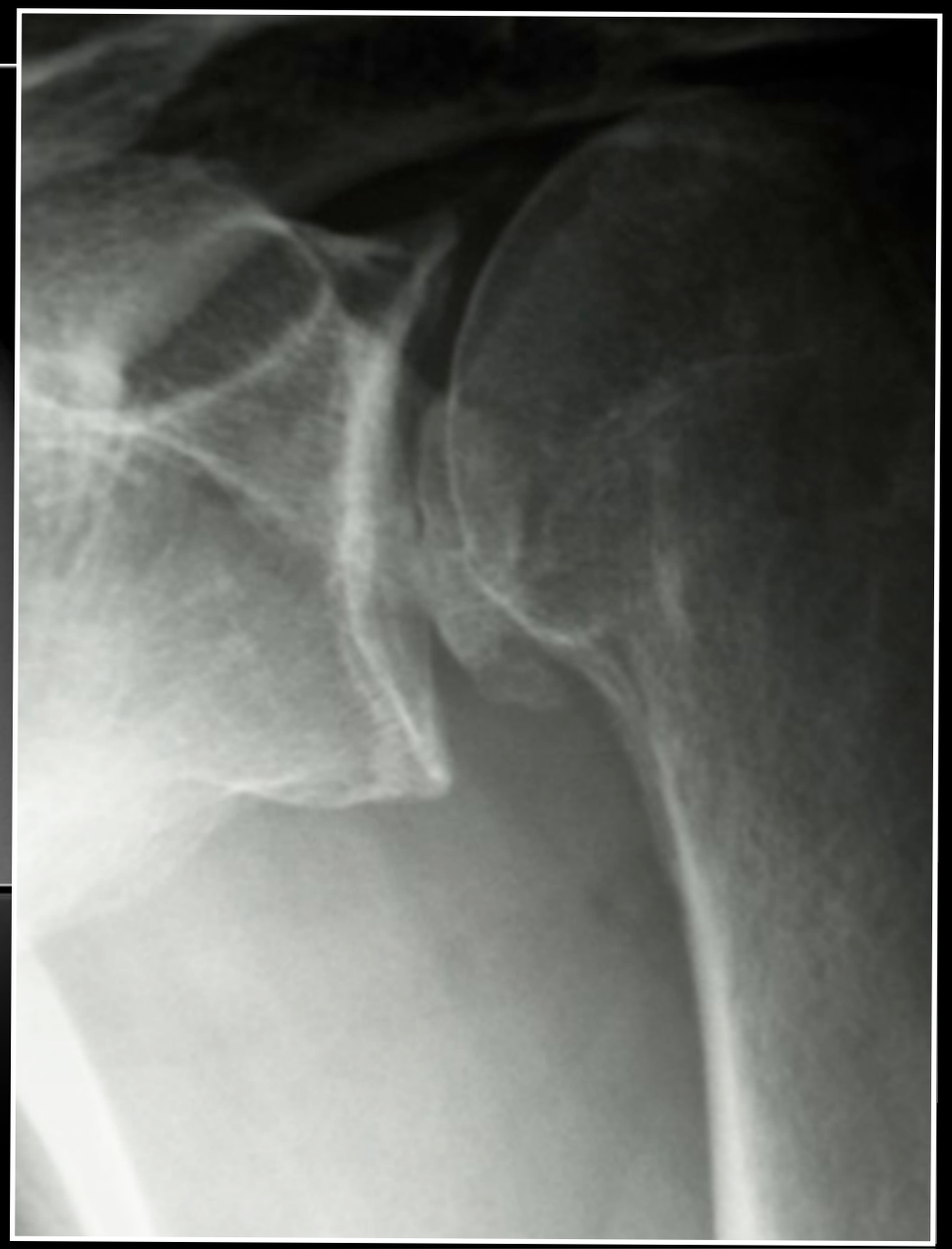

Necrosi avascolare-Osteonecrosi

Pseudoartrosi

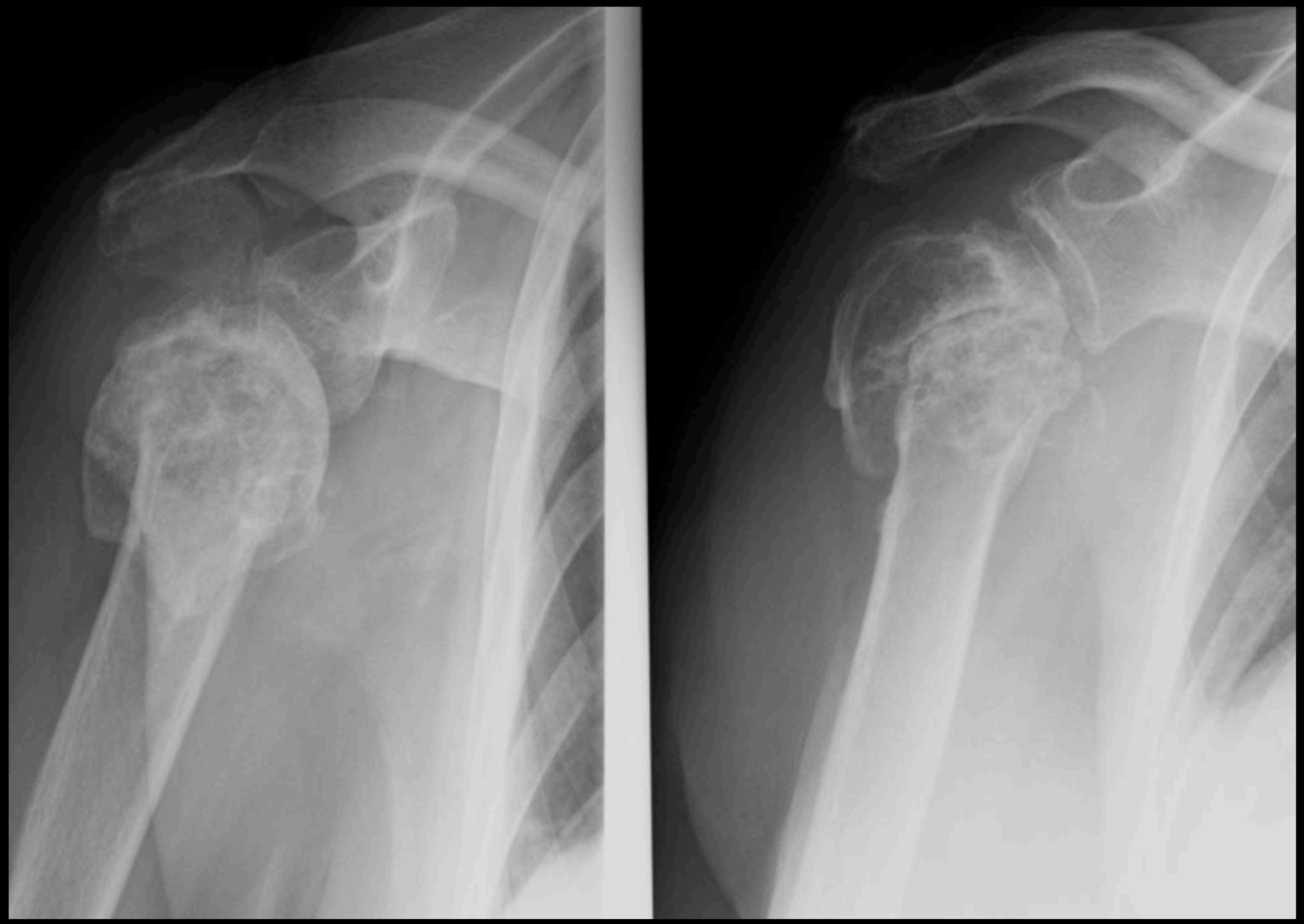

Samilson-Prieto Classification

Rx in AP in rotazione interna e in rotazione esterna
4 grades:

Normal;
Mild: osteophytes less than 3 mm on the humeral head or glenoid exostosis or both;
Moderate: osteophytes between 3 and 7 mm on the humeral head or the glenoid rim with slight glenohumeral-joint irregularity;
Severe: osteophytes of more than 7 mm with narrowing of the gleno-humeral joint and slerosis

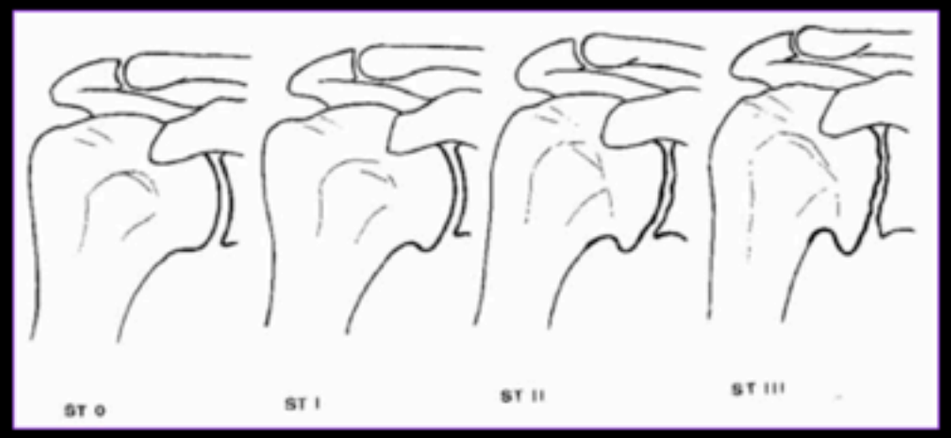

J Bone Joint Surg Am, 1983;65:456-460

Seebauer Classification

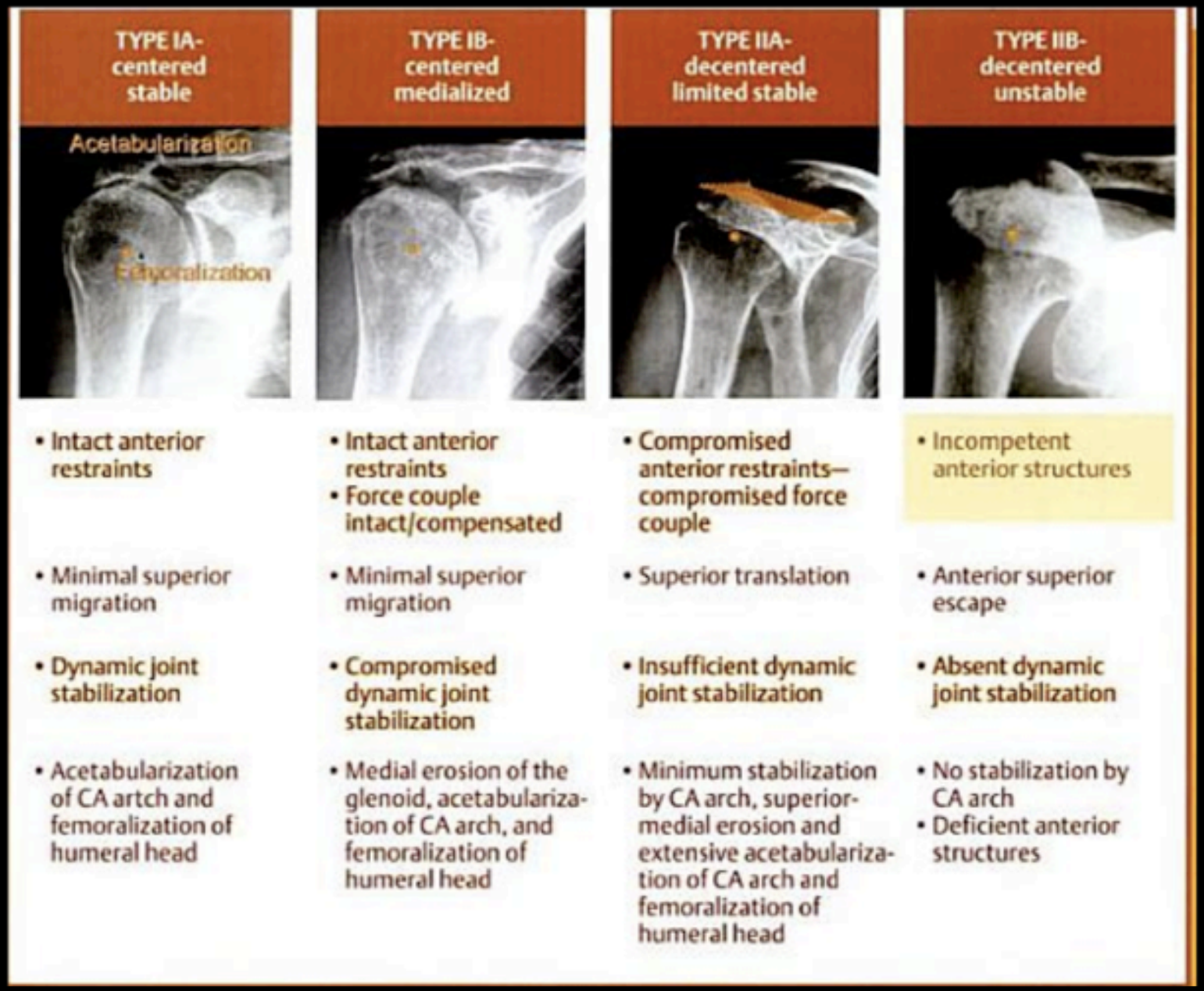

Cuff Tear Arthropathy: Pathogenesis, Classification, and Algorithm for Treatment

Jeffrey L. Visotsky, MD, Carl Basamania, MD, Ludwig Seebauer, MD, Charles A. Rockwood, MD and Kirk L. Jensen, M

JBJS Am. 2004;86:35-40, 2004

Hamada-Fukuda Classification

Hamada K,Fukuda H, et al:
Roentgenographic Findings in massive rotator cuff tears.A long term observation
Clin Orthop Relat Res 1990: Vol 254; 92-96

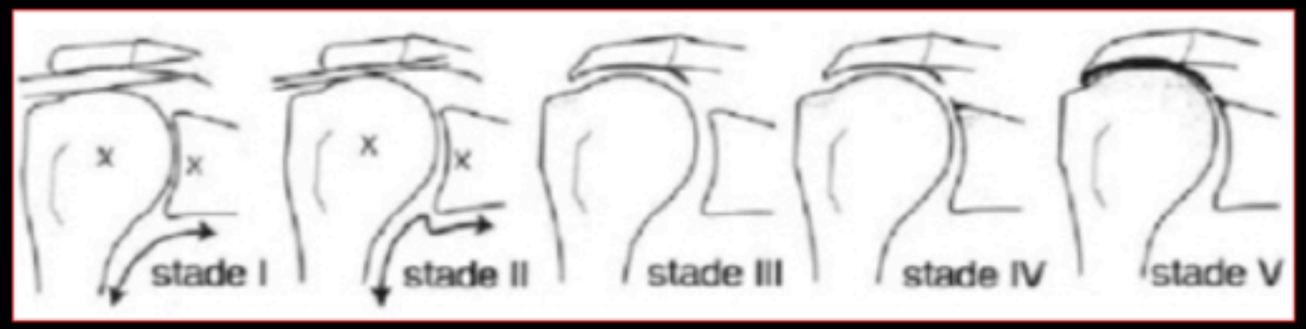

Grade 1: the acromiohumeral interval (AHI) is greater than 6 mm.
Grade 2 :the acromiohumeral distance is 6 mm or less.
Grade 3: Grade 2 +acetabulization, defined as a concave deformity of the acromion under the surface.
Grade 4 :narrowing of the glenohumeral joint is added to the grade 3 features.
Grade 5 :humeral head collapse is present which is characteristic of the cuff tear arthropathy.

Indicazioni

- Artrosi primaria
- Cuff Arthropaty
- Necrosi Avascolare
- Fratture a più frammenti
- Pseudoartrosi
- Artrite reumatoide
- Spondilite anchilosante

Pean 1884

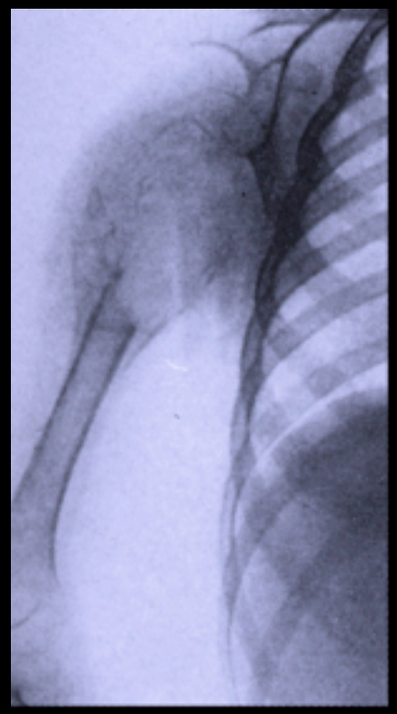

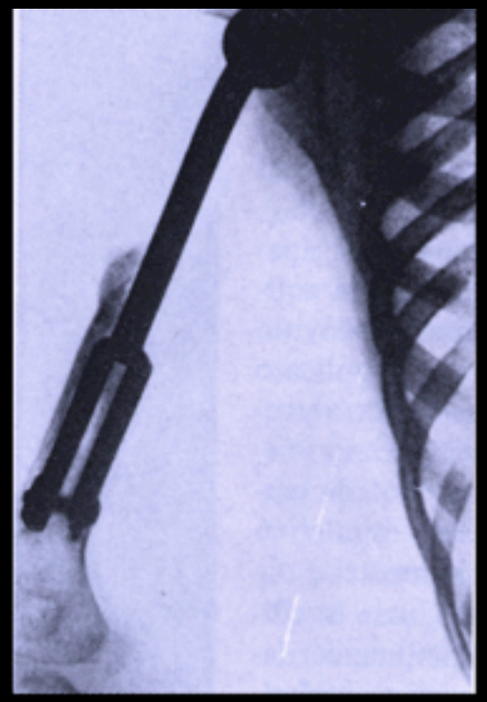

Delitala 1945

JUDET

1950

Protesi Vincolate

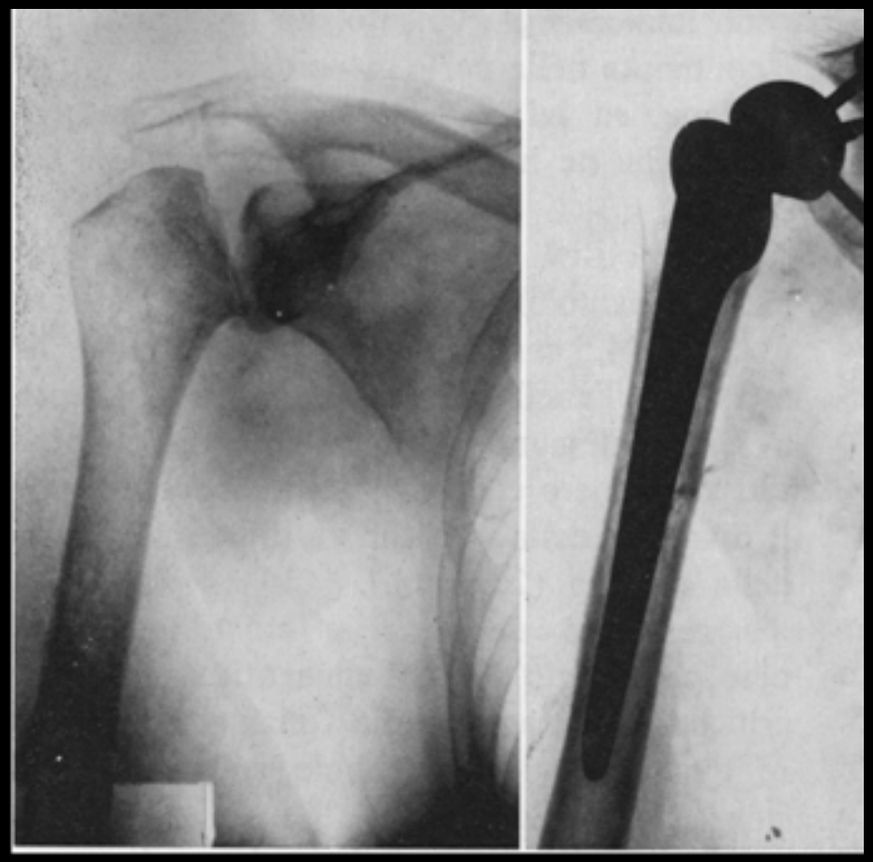

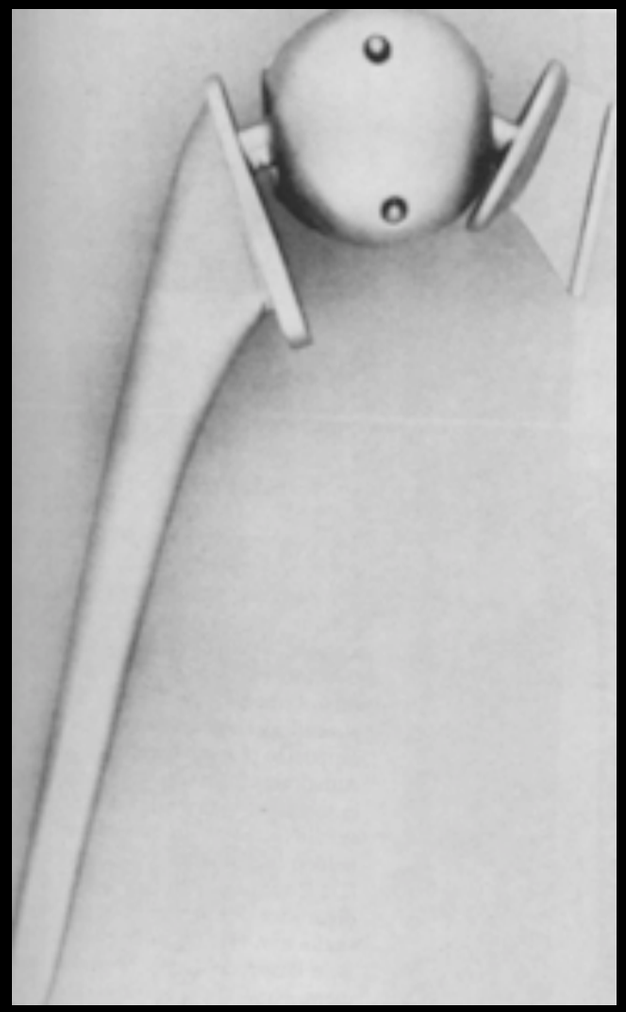

“The design of the prostheses should mimic the normal anatomy”

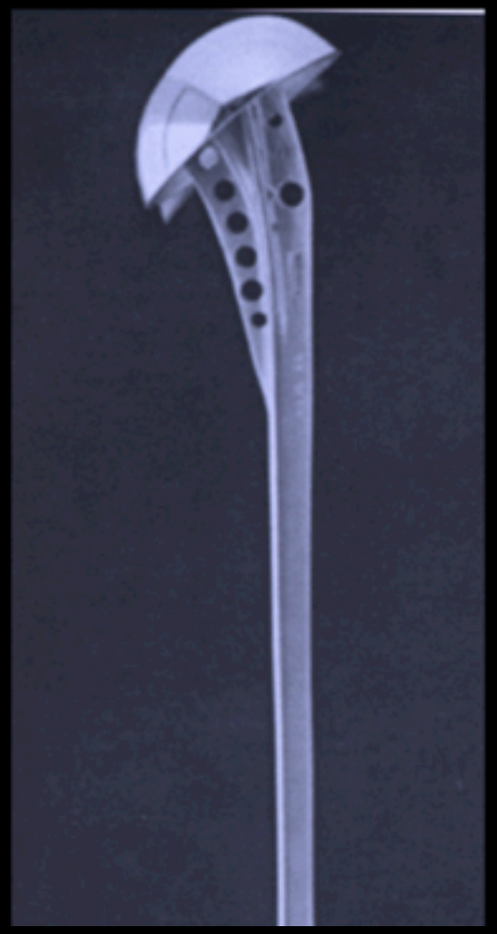

Neer fu il primo a comprendere che le protesi vincolate della spalla erano soggette a fallimento e che la sostituzione chirurgica della gleno-omerale doveva ripetere l'anatomia propria dell'articolazione; inoltre egli dimostrò che l'integrità della cuffia dei rotatori era la condizione necessaria alla funzione ottimale di una protesi anatomica, così come intuì che l'utilizzazione del polietilene per la riproduzione della glenoide e la sua fissazione con cemento acrilico fosse la scelta ottimale per rimuovere il dolore ed ottenere una buona funzione della spalla.

PROTESI INVERSA

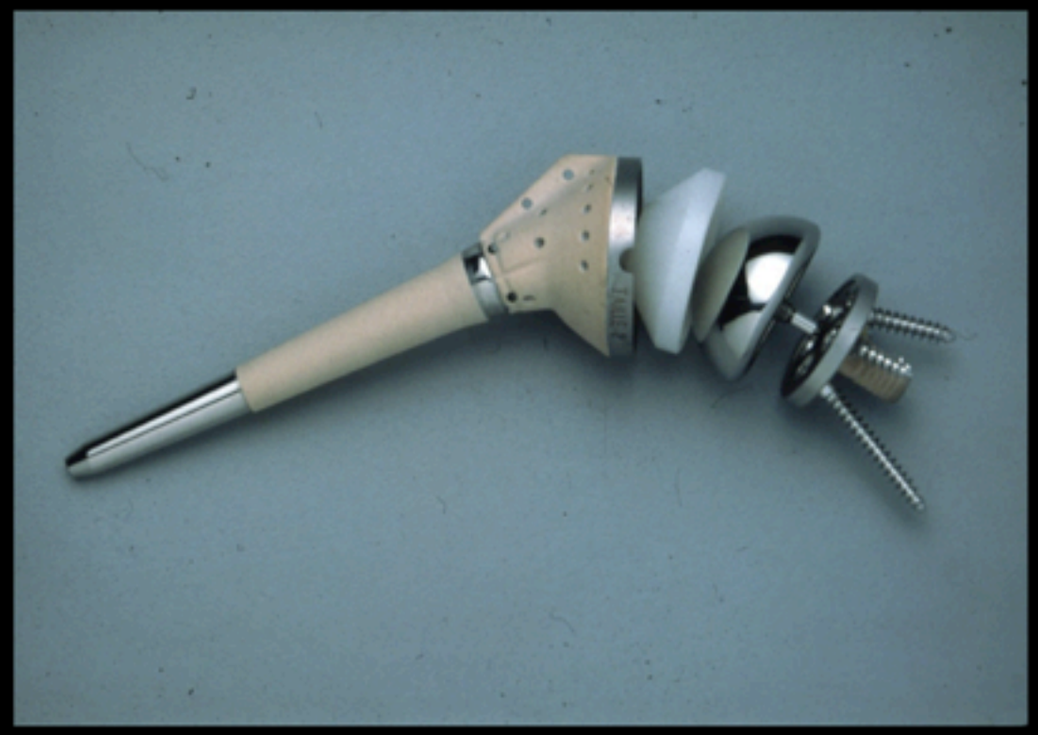

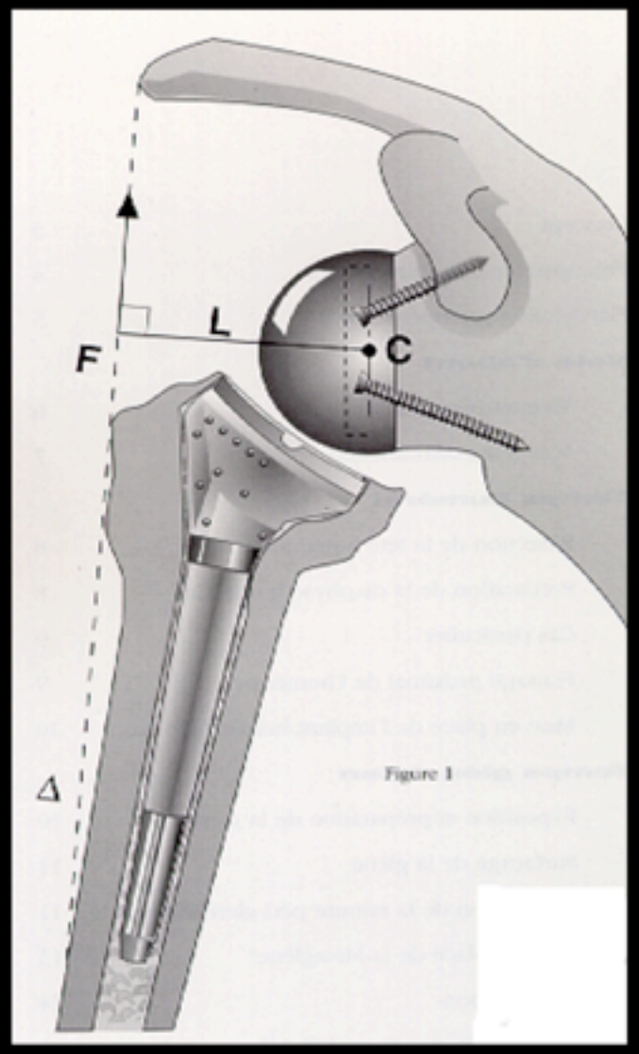

DS

13/05/1923
217341
DS

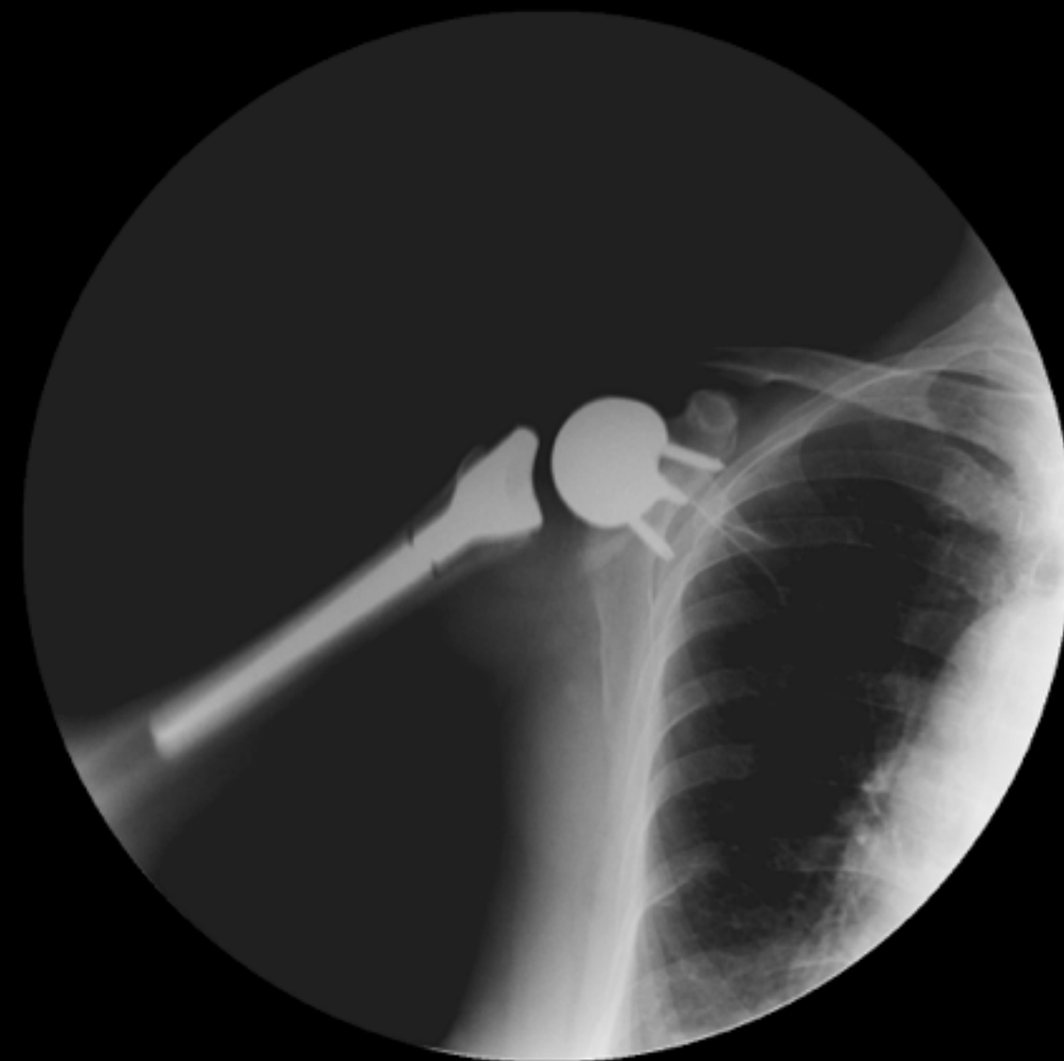

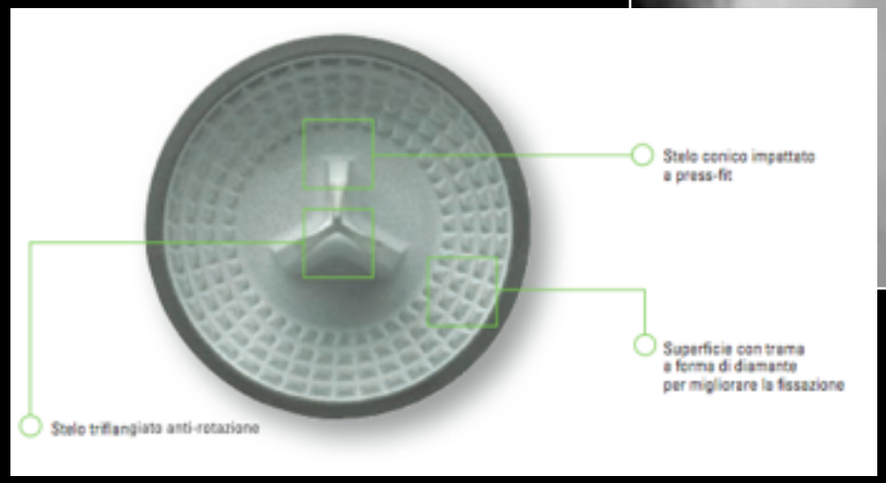
Stelo conico impattato
a press-fit
Superficie con trama
a forma di diamante
per migliorare la fissazione
Stelo triflangiato anti-rotazione

Biomet Copeland Resurfacing Head

Tornier Resurfacing Head

Zimmer Durom Shoulder Cup

Biomet Copeland EAS Humeral Resurfacing Head

DePuy Global CAP

Complicanze Precoci e Tardive

febbre;
infezioni superficiali e infezioni profonde
ematomi locali
cicatrici cheloidee

errori nel posizionamento delle componenti che possono determinare alterazioni della mobilità della spalla;

rigidità della spalla;
lussazione delle componenti protesiche;
mobilizzazione delle componenti protesiche;

Controindicazioni

infezioni in fase acuta;

paralisi o grave danno sia della cuffia dei rotatori sia del deltoide;

spalla neurologica.

Complicanze intraoperatorie:

Fratture durante le manovre chirurgiche

Lesioni vascolari

Lesioni nervose a carico del nervo ascellare o di altri rami del plesso brachiale.

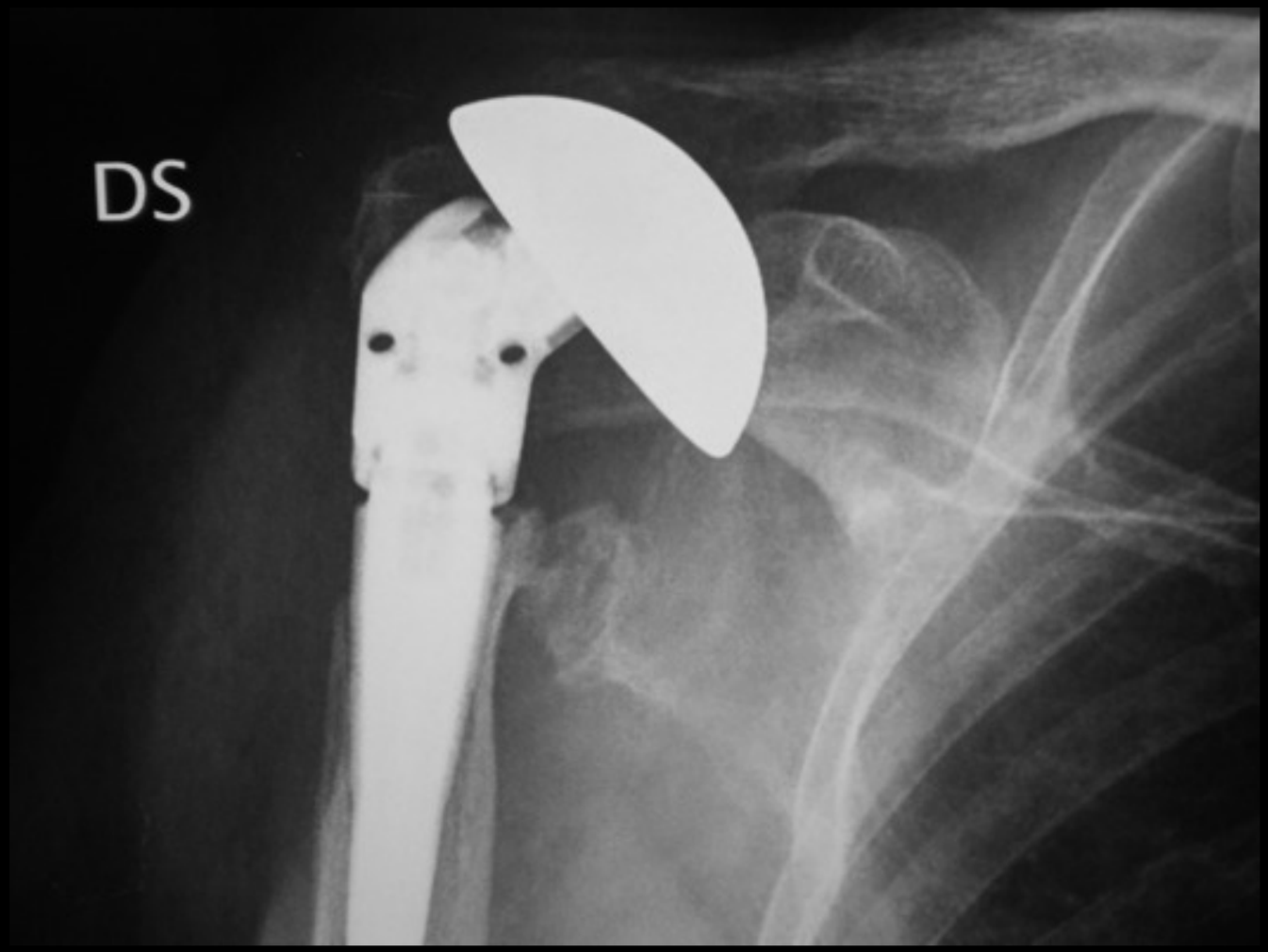
DS



ELSEVIER

Subscapularis insufficiency and the risk of shoul dislocation after reverse shoulder arthroplasty

T. Bradley Edwards, MD*, Matthew D. Williams, MD, Joanne E. Labriola Hussein A. Elkousy, MD, Gary M. Gartsman, MD, Daniel P. O'Connor, Ph

Fondren Orthopedic Group, Houston, TX

Hypothesis: Dislocation is the most common serious complication after reverse shoulder arthroplasty. One theorized cause is subscapularis insufficiency because the tendon cannot be repaired at the time of surgery. There are no documented risk assessments of reverse total shoulder arthroplasty dislocation related to this cause. The study objective was to quantify the risk of postoperative dislocation after reverse total shoulder arthroplasty in patients with a subscapularis tendon that was irreparable at the time of surgery.
Method: A prospective evaluation was done of 138 consecutive reverse arthroplasties performed through a deltopectoral approach by a single surgeon (average follow-up, 36 months).
Results: The subscapularis was reparable in 62 patients and irreparable in 76 at the conclusion of the procedure. Seven postoperative dislocations occurred; all dislocations were in patients whose subscapularis was irreparable ($P = .012$). Dislocations were more likely in patients with complex diagnoses, including proximal humeral nonunion, fixed glenohumeral dislocation, and failed prior arthroplasty.
Conclusions: This report documents that an irreparable subscapularis tendon at the time of reverse total shoulder arthroplasty using a deltopectoral approach results in a statistically significant risk for postoperative dislocation.
© 2009 Journal of Shoulder and Elbow Surgery Board of Trustees.
Keywords: Subscapularis; irreparable; reverse; shoulder; arthroplasty; complication; instability; dislocation

Paul Grammont[8] first reported his modern design for a reverse shoulder prosthesis in 1987. The reverse shoulder was initially designed for end-stage rotator cuff arthropathy and pseudoparalysis with inability to elevate the arm. The development and improvement of Grammont's original design has led to the reverse shoulder prosthesis becoming an important tool in the treatment of difficult shoulder pathologies.[4,5,13-15] The exciting treatment possibilities and results offered by the reverse prosthesis has led to an explosion of its use. However, the excitement must be tempered by the higher complication rate of reverse shoulder arthroplasty compared w shoulder arthroplasty. Studies of rev arthroplasty (TSA) that included mo have reported overall complication ra with dislocation rates of 0% to 9%.[3,1 studies, dislocations accounted for complications.

Causes of reverse TSA dislocation and include the number of prior p approach, bone deficiency, subscapu mechanical factors, and trauma. The li risk assessments of reverse TSA di known possible causes. Many patient TSA do not have a sufficient subscapul because of a chronic tear with re

*Reprint requests: Dr T. Bradley Edwards, 7401 S Main St, Houston, TX 77030-4300.
E-mail address: bend@fondren.com (T.B. Edwards).

"… an **insufficient subscapularis** at the time of reverse arthroplasty significantly increases the risk of postoperative dislocation when the procedure is performed through a deltopectoral approach …"

CELEBRATING 20 YEARS IN PUBLICATION

JOURNAL OF SHOULDER AND ELBOW SURGERY

Total shoulder arthroplasty with the neer prosthesis: Long-term results

Michael E. Torchia MD, Robert H. Cofield MD and Curtis R. Settergren MD

Department of Orthopedics, Mayo Clinic/Mayo Foundation, Rochester, Minn., USA.

Journal of Shoulder and Elbow Surgery
Volume 6, Issue 6, November-December 1997, Pages 495-505

The probability of implant survival was 93% after 10 years and 87% after 15 years.

Total shoulder arthroplasty: Long-term survivorship, functional outcome, and quality of life

September 2005

Ashwin V. Deshmukh, MD[a], Mark Koris, MD[b], David Zurakowski, PhD[b], Thomas S. Thornhill, MD[b]

he study group consisted of 320 consecutive TSAs performed in 267 patients between 1974 and 1988

80 patients with 103 TSAs at a mean of 15.4 ± 3.4 years after the index procedure (range, 10.4-23.2 years)

"...92% felt that their shoulder was "much better" or "better" after TSA."

Long-term analysis of the Neer-type TSA revealed survivorship rates comparable to other joint replacements. The significant improvements in relief of pain, shoulder range of motion, and strength are associated with a high degree of patient satisfaction.

La Protesi di spalla è sottoposta a minori carichi rispetto alla protesi di anca e ginocchio.
La sopravvivenza è significativamente maggiore e supera i 20 anni

Idealmente oltre i 65 anni

Anche sotto i 50 anni

Artrite Reumatoide

Emofilia

Necrosi ossea in seguito a terapia cortisonica

Artrosi post-traumatica

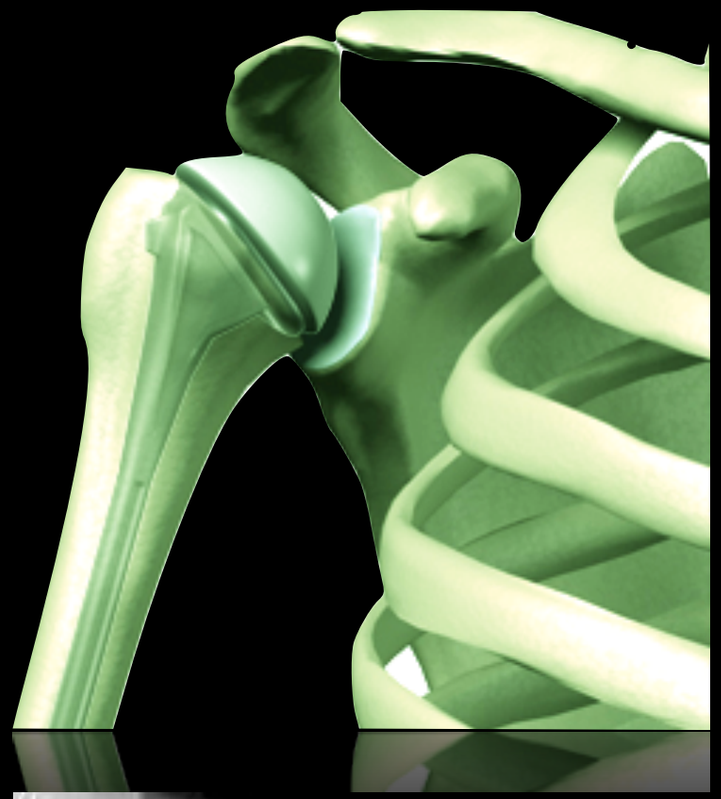

Hemiarthroplasty

1) Young active patients with intact glenoid
2) Insufficient bone
3) Acute fractures
4) CTA with balanced force couples

Emiartroplastica

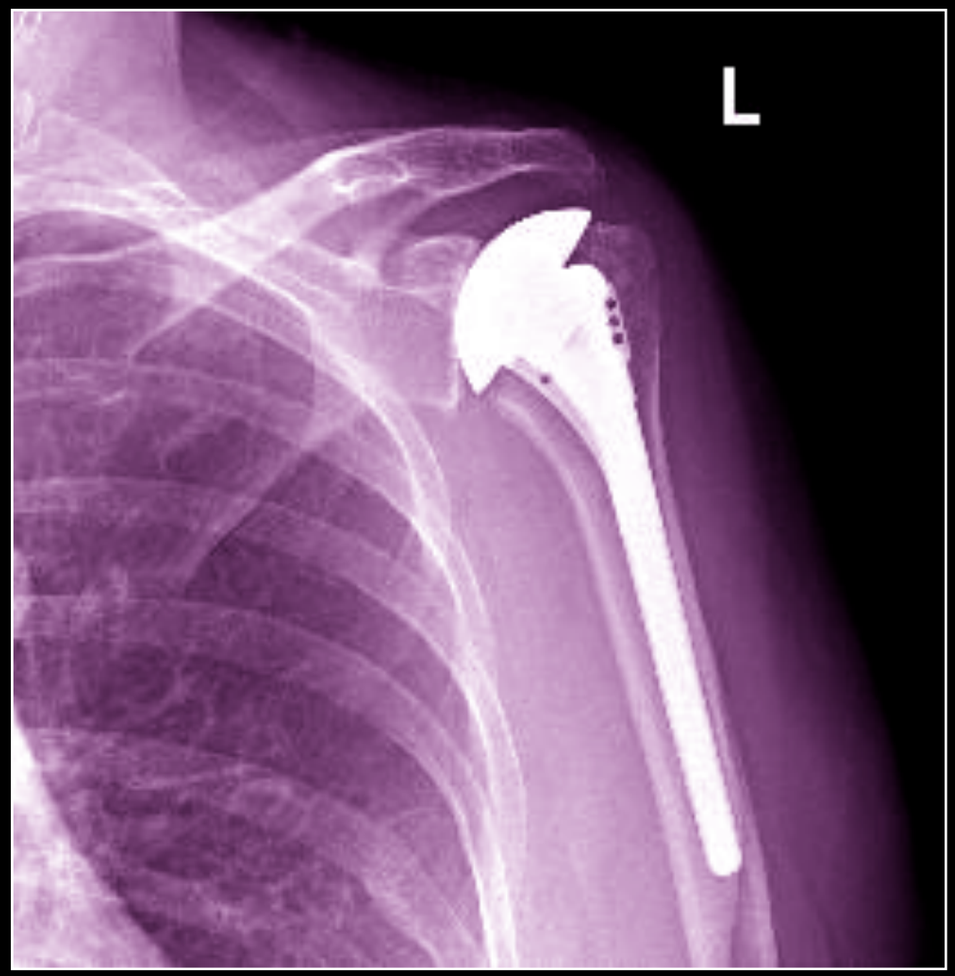

PROTESI GLENOIDEA



Metal back o polietilene?

Fondo piatto o convesso?

Cementata o non cementata?

Più o meno congruente ?

Pinna o perni ?

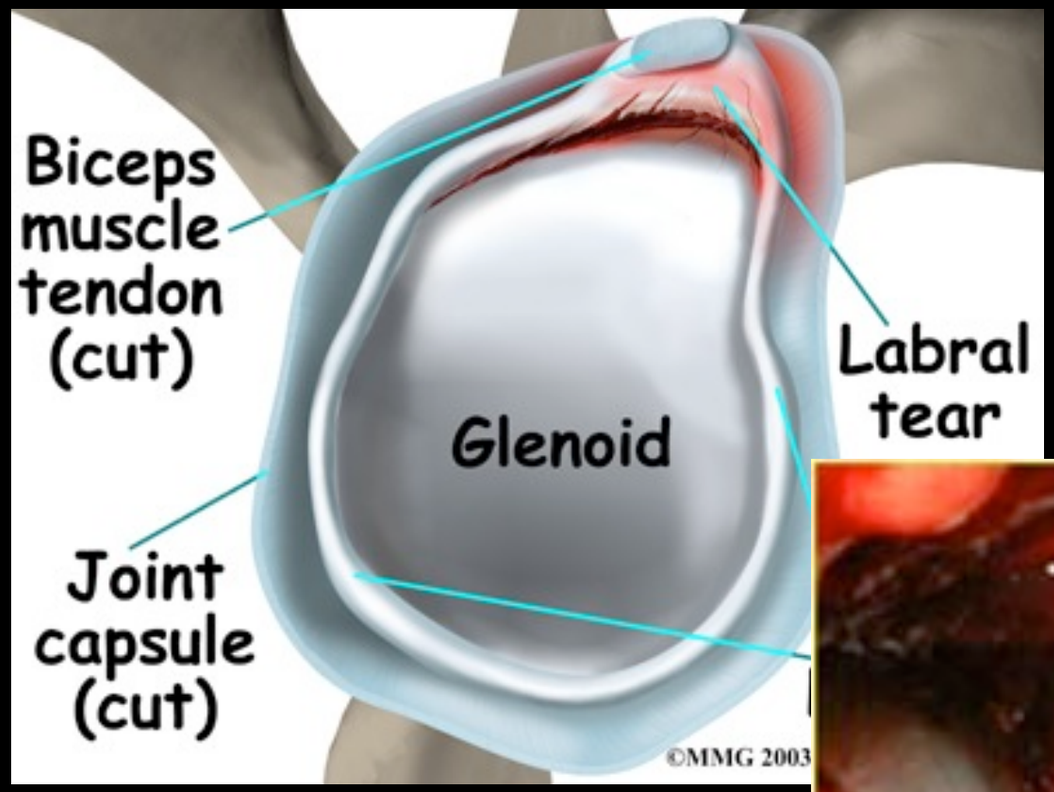
Biceps muscle tendon (cut)
Glenoid
Labral tear
Joint capsule (cut)
©MMG 2003

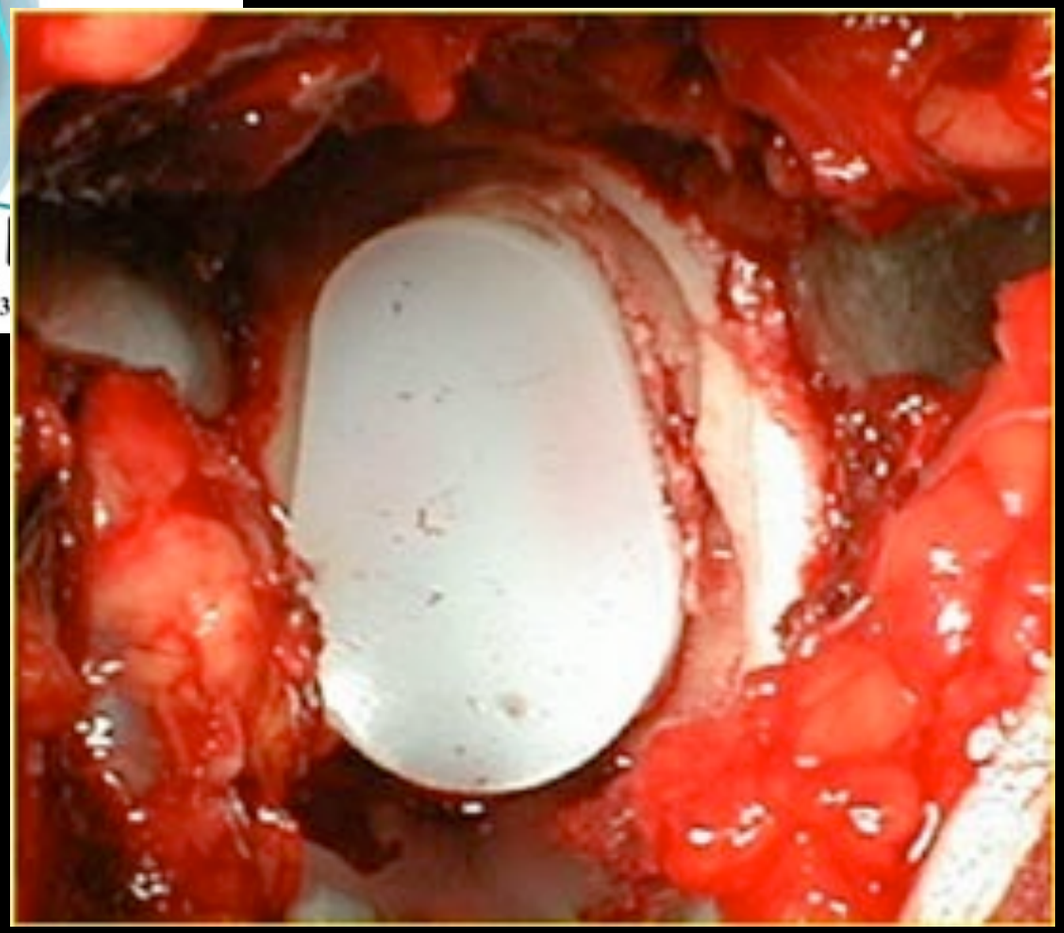

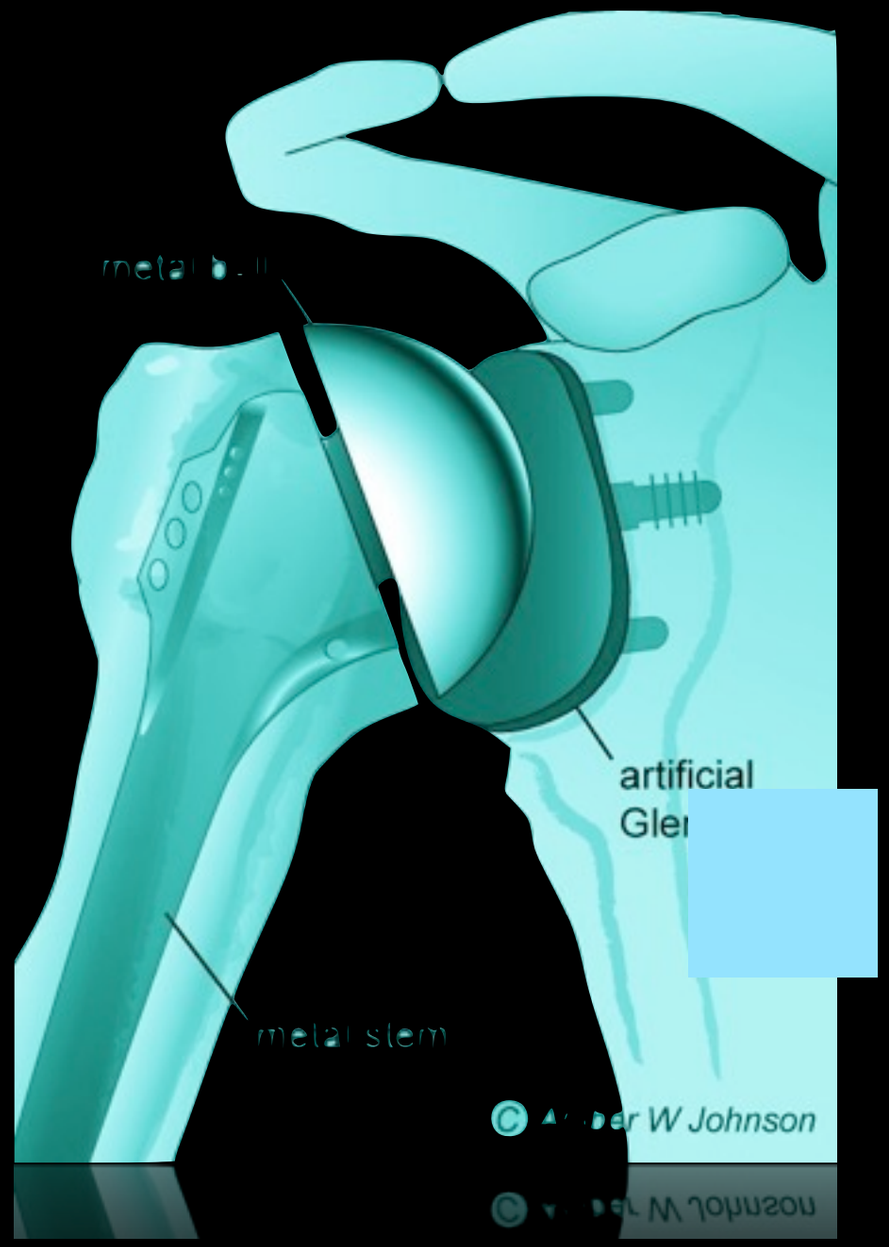

Total Shoulder A-plasty

1) Osteoarthritis
2) Rheumatoid arthritis with an intact cuff
3) Incongruency of the glenoid
4) Adequate glenoid bone stock

Total Shoulder Arthroplasty

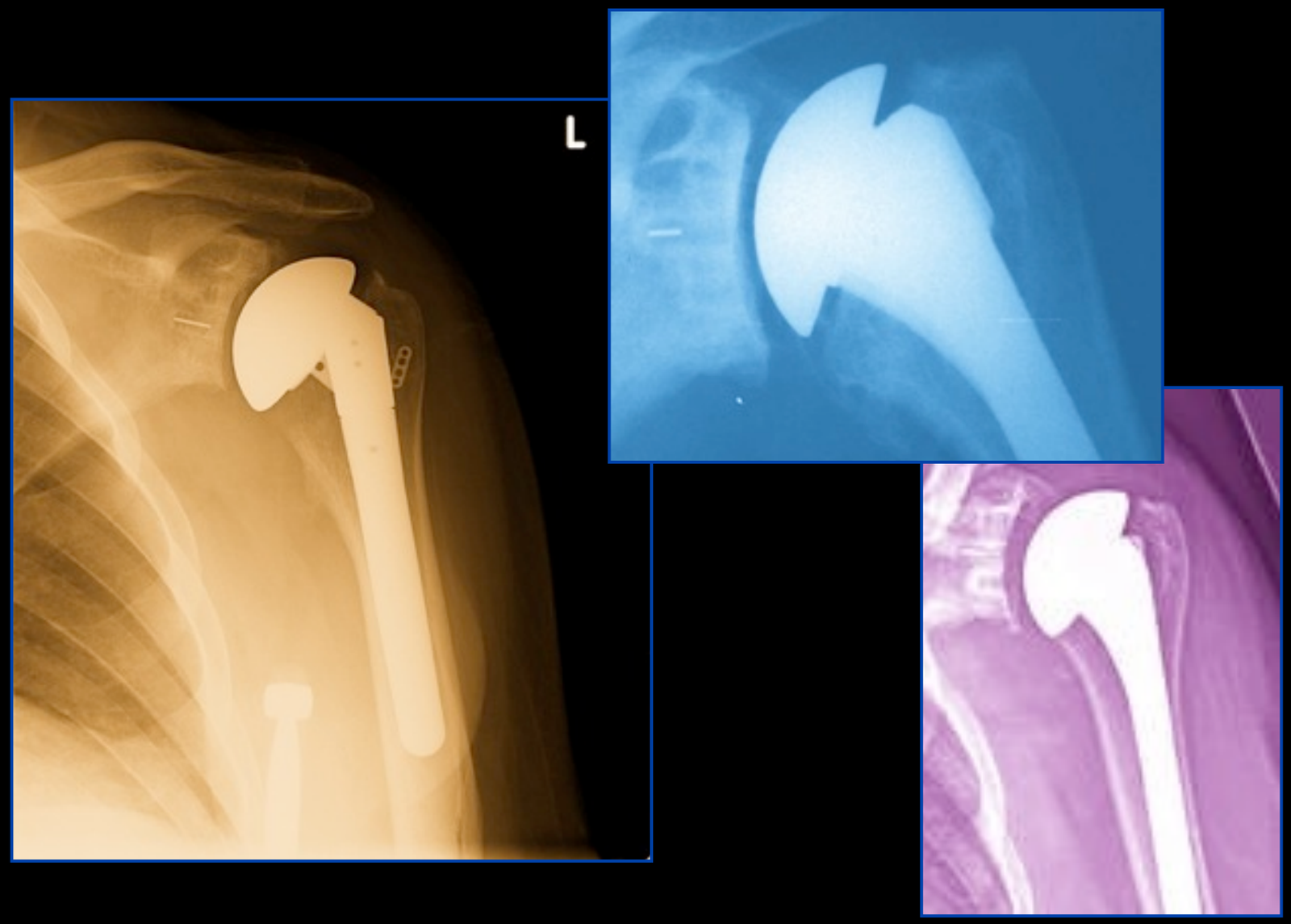

Frattura a più frammenti

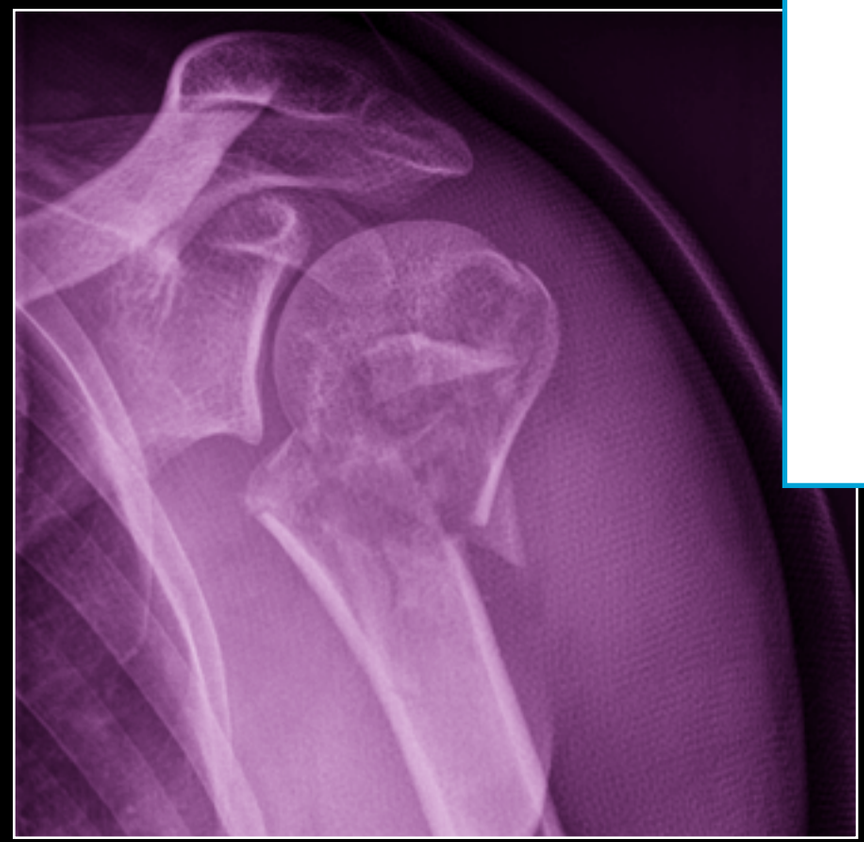

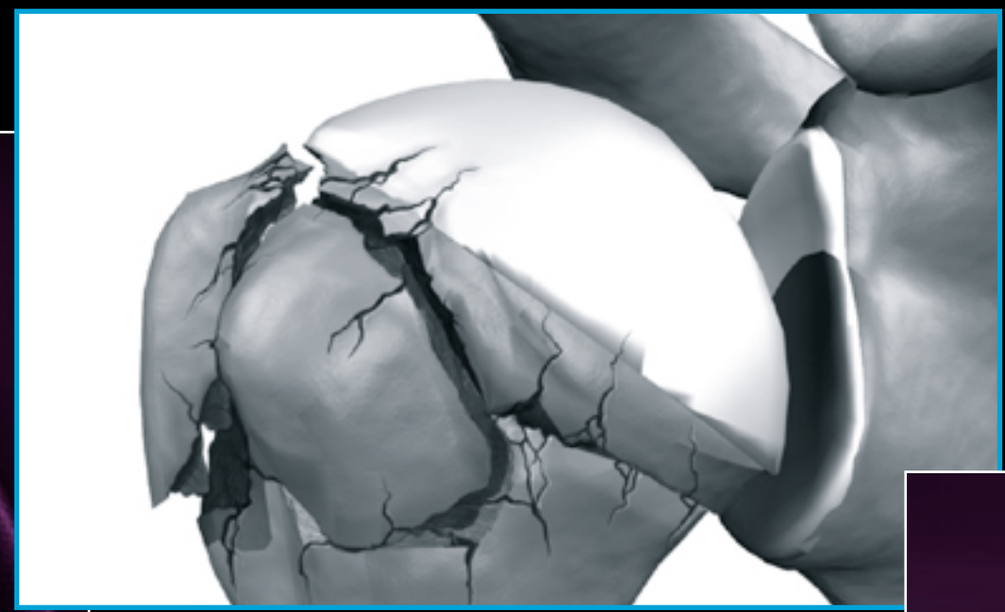

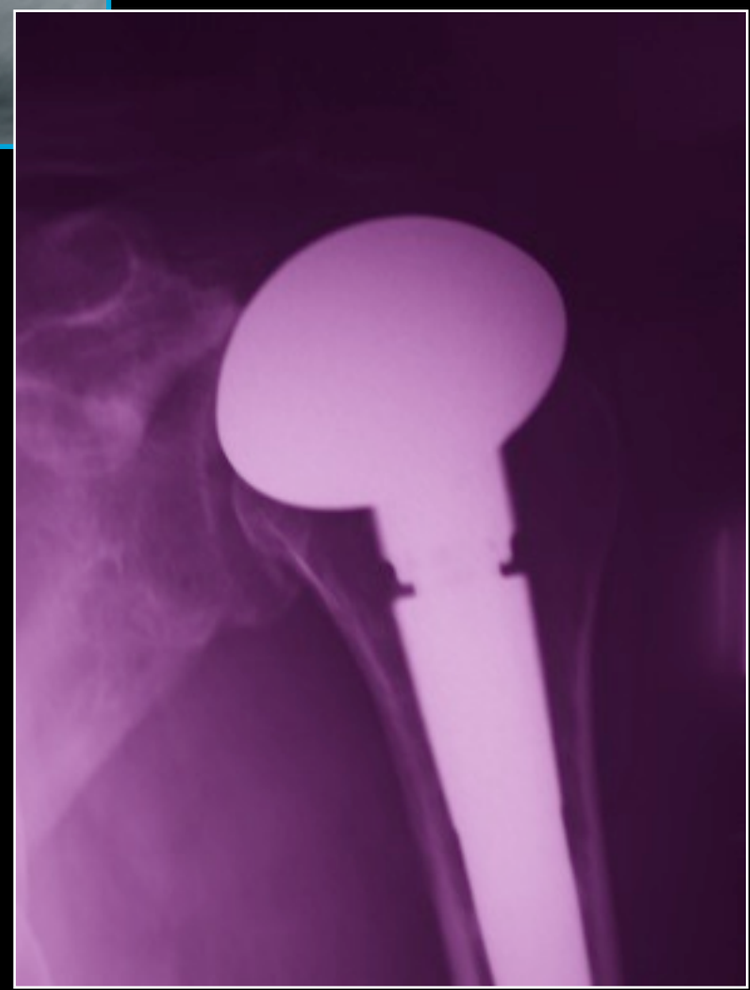

Errori Tecnici che si ripercuotono sulla fase Rieducativa

Protesi alta o protesi bassa

- Protesi sovradimensionata o insufficiente
- Errore di versione della testa
- Errore di posizionamento delle tuberosità
- Errore di versione dell'impianto glenoideo
- Eccessivo o alterato bilanciamento dei tessuti molli

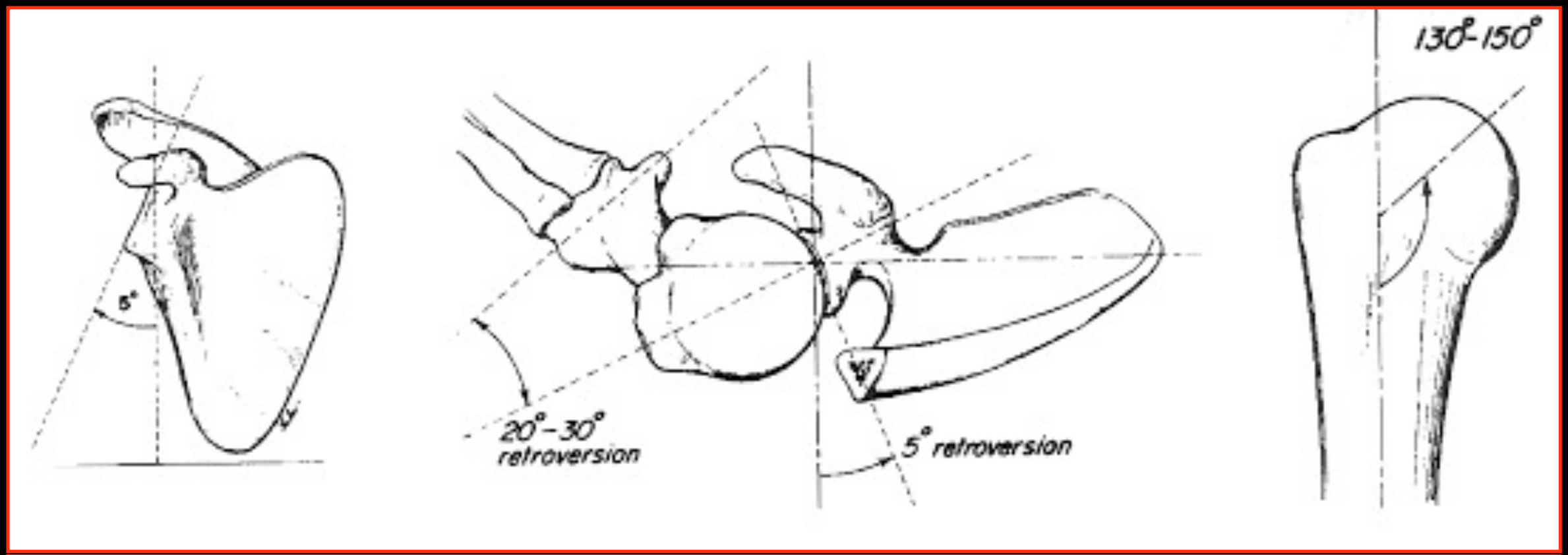
130°-150°
5°
20°-30°
retroversion
5° retroversion

Le possibili cause di una rigidità tissutale:

- Ritardo nell'inizio delle mobilizzazioni passive
- Ridotta efficacia delle mobilizzazioni passive
- Inadeguato o eccessivo numero di sedute rieducative
- Inadeguato numero di esercizi domiciliari
- Presenza del dolore
- Paziente poco collaborante

I progressi della protesizzazione della spalla vanno ritrovati in:

Evoluzione Tecnologica

Disegno
Modularità

Precisazione delle indicazioni

Accuratezza delle indicazioni

Stretta collaborazione Chirurgo-Riabilitatore

PERCHE’ DOVREI ?

Elimina o migliora i sintomi dolorosi





Migliora decisamente la funzione dell’ arto

Migliora la forza

Aiuta nel riprendere una normale vita di relazione



Ospedalizzazione e Periodo Post-operatorio

Il Ricovero dura normalmente 2-3 notti.
Il Paziente viene dimesso con un tutore in abduzione per 3 settimane circa
Mobilizzazione del gomito da subito
FKT Passiva dopo 15 gg;
Fkt attiva dopo circa 20-25 gg

MEGLIO EVITARE L' INTERVENTO SE...

Se penso che tanto è meglio tirare avanti cosi e poi si vedrà...
Se penso che si accontenta gode...
Se non credo di potere ritornare ad una soddisfacente autonomia
Se ho severe patologie generali

Sospesi fra Prestazione e Patologia ...

...è una questione di equilibrio fra richiesta funzionale e limiti fisiologici

Tabulae Anatomicae

Venice, 1627. Copperplate engraving. National Library of Medicine.

Giulio Casserio
(ca. 1552-1616)
[anatomist]

Odoardo Fialetti
[artist]

Grazie